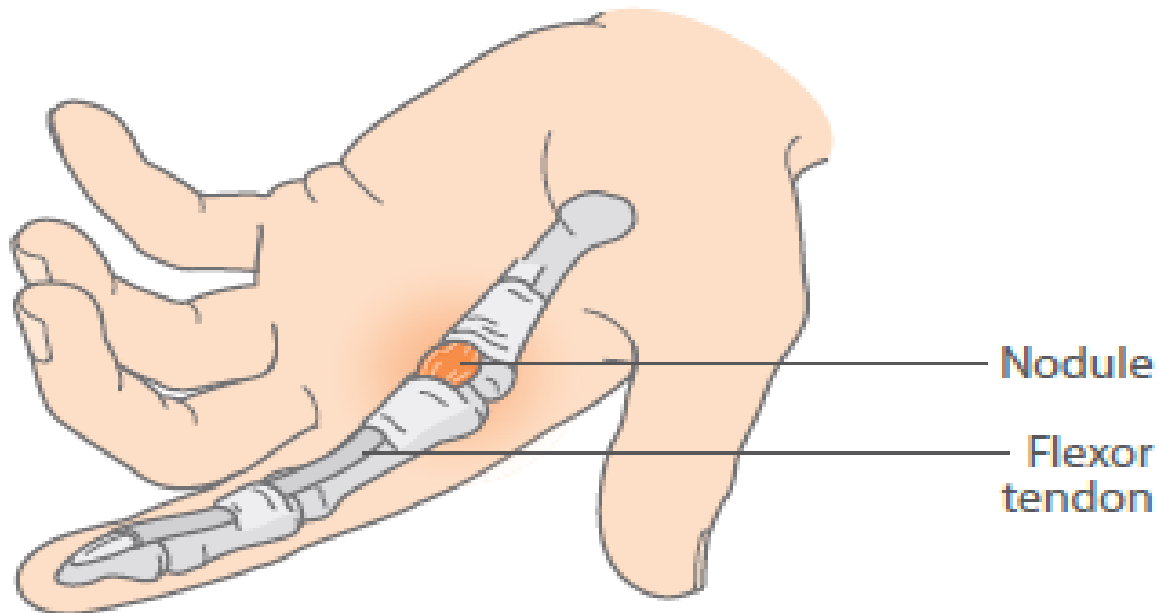


# TRIGGER FINGER

Shamarli Mendis

# Trigger Finger



**Trigger finger showing the flexor tendons of the index finger with the pulleys holding them in place and an inflammatory 'trigger nodule'.**

# Aetiology and Treatment options

- Primary- Isolated trigger finger, Congenital
- Secondary- Diabetes, RA, Gout
  
- Treatment: Can use splints(conservative approach)
- Steroid injections placed within tendon sheath
- Surgical release- irreducible locked trigger finger should be referred urgently to prevent permanent contracture of finger